



DATE PRESENTING CLINICAL SIGNS

10/11/22

patient presented for hemorrhagic diarrhea for 3 months. Enlarged spleen on abdominal U/S. Enlarged mesenteric LNs as well. FNAs taken of both.

INTERPRETED BY

L.D. McGill, DVM,
Ph.D, DACVP

CYTOLOGY SUBMISSION

FNA of Lymph Node

PATIENT

Minnie Orange Street
Cat Rescue

OBSERVATIONS

Lymph node: Submitted are 20 excellent images of cells collected from the lymph node in Minnie. The majority of the cells are small mature lymphocytes. They have nuclei that are approximately the size of red blood cells. There are scattered reactive lymphoid cells and there are scattered neutrophils and macrophages. This lymphoid tissue does not suggest a neoplastic process.

SPECIES

Feline

INTERPRETATION OF THE FINDINGS & FURTHER RECOMMENDATIONS

BREED

Lymph node - Reactive lymphoid tissue with mild suppurative lymphadenitis.

DSH

SEX

spayed female

COMMENTS

The cellularity in this collection is characteristic of inflammation draining to the lymph node with reactive lymphoid tissue. The cells do not support neoplasia. This inflammation could be from the intestine or even pancreas since there could also be pancreatitis. This is the same type of inflammation that may be in the spleen. If there is lymphoma in the intestine, those cells will often not involve the mesenteric lymph nodes. This is due to the fact that they have markers that only allow them to grow in the intestine. Therefore, at this time, we do not have information as to what is occurring in the intestine. There could be inflammation or there could be neoplasia. The inflammation in the lymph nodes could be secondary to either. Exploratory and biopsies of the intestine will likely be required to confirm the underlying process.

AGE

3 yo

WEIGHT

7 lb

HOSPITAL NAME

Central Veterinary
Hospital

REFERRING VET

Dr. Anna St. Sir

INVOICE NUMBER

40622



DATE

10/11/22

INTERPRETED BY

L.D. McGill, DVM,
Ph.D, DACVP

PATIENT

Minnie Orange Street
Cat Rescue

SPECIES

Feline

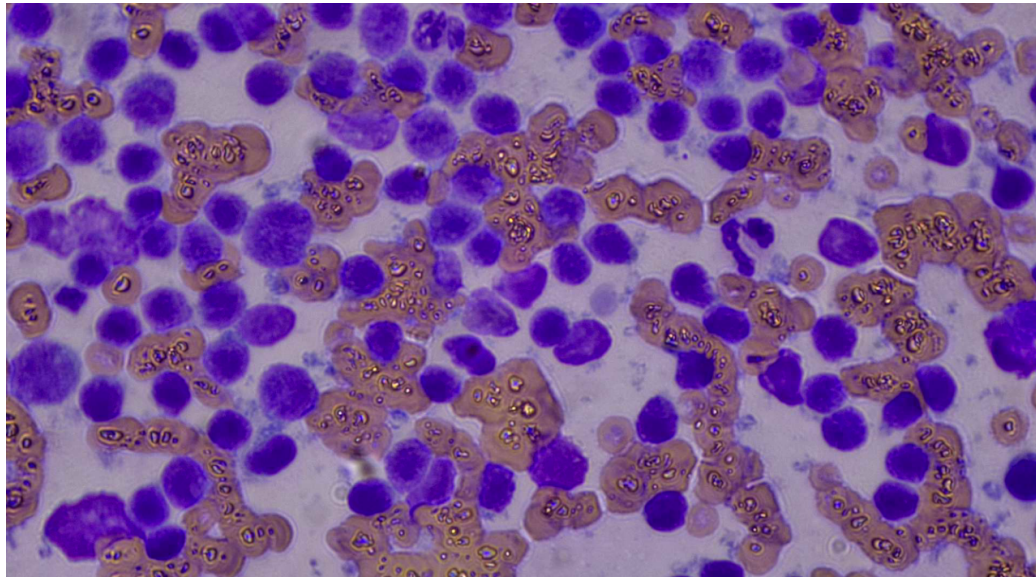


Image shows a uniform group of small lymphocytes with scattered reactive lymphocytes and a neutrophil. This cellularity does not support neoplasia.

BREED

DSH

The information and recommendations provided are based on the images presented by the referring veterinarian. No evaluation can be communicated regarding pathology that was not visible in the image/video clips provided.

SEX

spayed female

Thank you for this referral. If the clinical or image interpretation does not parallel your findings or if I can be of any further assistance, please contact me.

AGE

3 yo

L.D. McGill, DVM, Ph.D., DACVP
8288 Top of the World Drive
Cottonwood Heights, UT 84121
ldmcgill.vetpath@gmail.com
cell: 801-865-1220

WEIGHT

7 lb

HOSPITAL NAME

Central Veterinary
Hospital

REFERRING VET

Dr. Anna St. Sir

INVOICE NUMBER

40622